

National Board of Osteopathic Medical Examiners

Foundational Biomedical Sciences Practice Exam

Organized by Body System

NBOME[®]

NATIONAL BOARD OF OSTEOPATHIC MEDICAL EXAMINERS

Contents

| | |
|---------------------------------------------------------------------|----|
| HUMAN DEVELOPMENT, REPRODUCTION, AND SEXUALITY | 2 |
| HUMAN DEVELOPMENT, REPRODUCTION, AND SEXUALITY ANSWER KEY | 4 |
| ENDOCRINE SYSTEM AND METABOLISM..... | 5 |
| ENDOCRINE SYSTEM AND METABOLISM ANSWER KEY | 7 |
| NERVOUS SYSTEM AND MENTAL HEALTH | 8 |
| NERVOUS SYSTEM AND MENTAL HEALTH ANSWER KEY | 10 |
| MUSCULOSKELETAL SYSTEM..... | 11 |
| MUSCULOSKELETAL SYSTEM ANSWER KEY | 13 |
| GENITOURINARY/RENAL SYSTEM..... | 14 |
| GENITOURINARY/RENAL SYSTEM ANSWER KEY | 16 |
| GASTROINTESTINAL (GI) SYSTEM AND NUTRITIONAL HEALTH | 17 |
| GASTROINTESTINAL (GI) SYSTEM AND NUTRITIONAL HEALTH ANSWER KEY..... | 19 |
| CARDIOVASCULAR AND HEMATOLOGIC SYSTEMS..... | 20 |
| CARDIOVASCULAR AND HEMATOLOGIC SYSTEMS ANSWER KEY | 22 |
| RESPIRATORY SYSTEM | 23 |
| RESPIRATORY SYSTEM ANSWER KEY | 26 |
| INTEGUMENTARY SYSTEM | 27 |
| INTEGUMENTARY SYSTEM ANSWER KEY | 28 |

Human Development, Reproduction, and Sexuality

1. A 17-year-old girl presents to the office for a health maintenance examination. Questioning reveals that she experienced menarche 5 years ago; her menses are regular. The patient does not use any form of contraception. What is most likely present as this patient transitions from the follicular phase to the luteal phase of her next cycle?
 - a. decreased estradiol level
 - b. greater follicle-stimulating hormone level than luteinizing hormone level
 - c. meiotic division of ova
 - d. peaked progesterone level
 - e. uterine lining at its smallest thickness

2. A 20-year-old man presents to the office with a 2-week history of a lump on his left testis. Physical examination reveals a solid, 2-cm mass on the left testis and lymphadenopathy in the left supraclavicular region. Cancerous cells spreading from this patient's lesion via venous channels will most directly reach which of the following structures?
 - a. adrenal gland
 - b. kidney
 - c. lung
 - d. sternum
 - e. thyroid

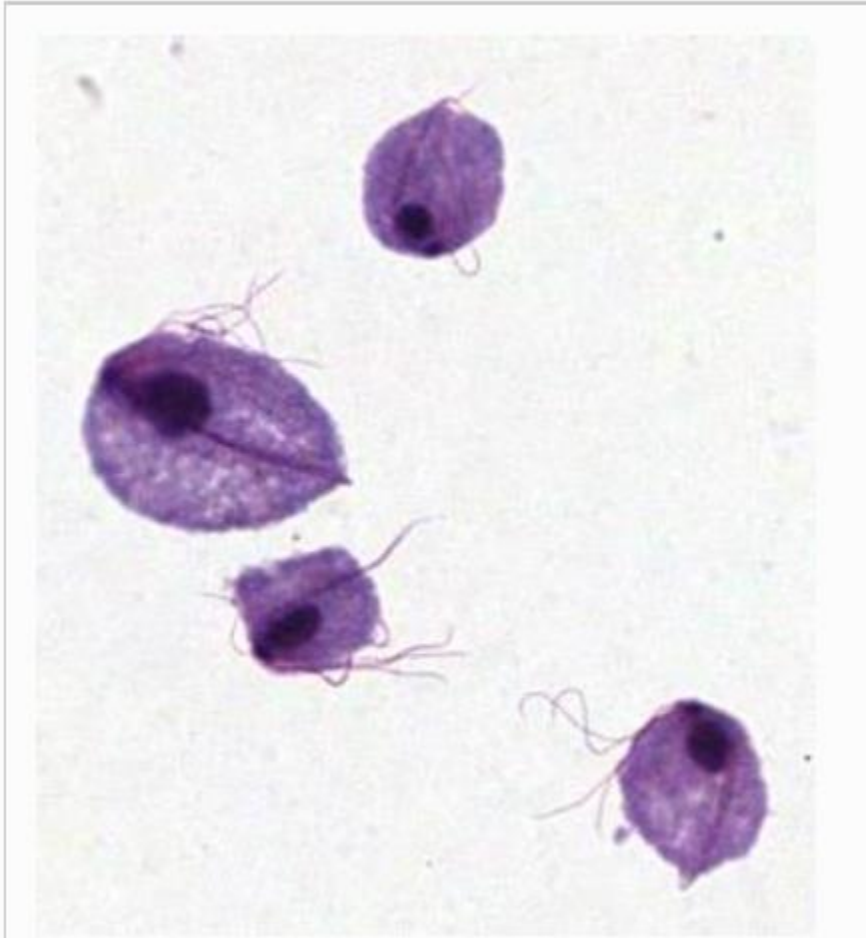3. A 14-year-old boy is brought to the office by his father, who is concerned about the patient's lack of physical development. He is at the 95th percentile for height and the 40th percentile for weight. Physical examination reveals small testes, enlarged breasts, and a lack of male secondary sexual characteristics. Laboratory studies reveal:

| Test | Patient's Value | Reference Range |
|-------------------------------------|-----------------|-----------------|
| Testosterone | 250 ng/dL | 31-733 ng/dL |
| Follicle-stimulating hormone | 17.3 mIU/mL | 1.4-15.4 mIU/mL |
| Luteinizing hormone | 13.4 mIU/mL | 1.0-10.2 mIU/mL |

This patient's most likely karyotype is

- a. 46XrY
- b. 46XY
- c. 47XXY
- d. 47XY+21
- e. 47XYY

4. A 22-year-old woman presents to the office with a 2-day history of vaginal itching and frothy discharge. Past medical history is unremarkable. Social history reveals that she became sexually active at 18 years of age; she has had 4 sexual partners. A wet mount reveals 0.01-mm motile organisms. An iodine-stained preparation of the discharge reveals the findings shown in the exhibit.



The most likely etiologic agent belongs to which of the following genera?

- a. *Chilomastix*
- b. *Entamoeba*
- c. *Gardnerella*
- d. *Giardia*
- e. *Trichomonas*

5. A 10-year-old girl is brought to the office by her parents, who are concerned about her diminutive stature. She is below the 5th percentile for height and weight. Vital signs are normal. The patient is diagnosed with idiopathic growth hormone deficiency, and she is treated with growth hormone. This patient's treatment is most likely to cause increased levels of which of the following hormones?
- a. epinephrine
 - b. estradiol
 - c. insulinlike growth factor 1
 - d. luteinizing hormone
 - e. triiodothyronine

Human Development, Reproduction, and Sexuality Answer Key

| Question | Answer |
|----------|--------|
| 1. | a |
| 2. | c |
| 3. | c |
| 4. | e |
| 5. | c |

Endocrine System and Metabolism

6. A 57-year-old man presents to the office with his wife for a health maintenance examination. The patient has no complaints. On questioning, the patient says that he and his wife have been traveling frequently and have taken trips to visit their grandchildren. He also says that he purchased several apartment buildings and earned large sums of money in the past few months. The wife asks to speak to the physician alone and discloses that her husband has been coming up with untrue stories like this. She says that the patient's alcohol use has increased over the past 5 years, and he now consumes up to a fifth of bourbon daily. The most likely cause of this patient's presentation is degeneration of neurons in the
- anterior hypothalamic area
 - arcuate nucleus
 - dorsal hypothalamic area
 - lateral hypothalamic area
 - mammillary bodies
7. A 35-year-old woman presents to the office with a 10-day history of a bilateral hand tremor, palpitations, a gritty sensation in her eyes, and light sensitivity that have been slowly worsening. Vital signs reveal:

| | |
|------------------|-------------|
| Blood Pressure | 134/86 mmHg |
| Heart Rate | 110/min |
| Respiratory Rate | 18/min |

Physical examination reveals:

- Bilateral exophthalmos
- Bilateral chemosis
- Tender, enlarged thyroid
- Thick, erythematous skin on the pretibial regions

Laboratory studies reveal:

| Test | Patient's Value | Reference Range |
|------------------------------------|-----------------|-----------------|
| Total triiodothyronine | 300 ng/dL | 70-204 ng/dL |
| Total thyroxine | 14 mcg/dL | 5.5-11.0 mcg/dL |
| Thyroid-stimulating hormone | 0.2 mcIU/mL | 0.4-4.2 mcIU/mL |

The physiologic mechanism of this patient's condition is most likely due to the development of autoantibodies against

- CD4 receptors
- nicotinic receptors
- thyroid peroxidase
- thyroid-stimulating hormone receptors
- tyrosine kinase receptors

8. A 14-year-old boy is brought to the office with a 1-month history of fatigue and excessive thirst. He also says that he has to go to the bathroom all the time. Vital signs reveal:

| | |
|------------------|-----------------|
| Temperature | 37.0°C (98.6°F) |
| Blood Pressure | 95/60 mmHg |
| Heart Rate | 95/min |
| Respiratory Rate | 15/min |

His fasting blood glucose level is 210 mg/dL (reference range: 60-100 mg/dL). He is administered a hormone that reduces his fasting blood glucose level to 75 mg/dL. This treatment is most likely to cause which of the following changes in this patient's hepatic carbohydrate metabolism?

| | Glycolysis | Gluconeogenesis | Glycogen Synthesis |
|-----------|-------------------|------------------------|---------------------------|
| A. | decreased | decreased | decreased |
| B. | decreased | decreased | increased |
| C. | decreased | increased | decreased |
| D. | increased | decreased | increased |
| E. | increased | increased | decreased |
| F. | increased | increased | increased |

- a. A
 b. B
 c. C
 d. D
 e. E
 f. F
9. A 15-year-old boy presents to the office with a 2-week history of nausea, vomiting, loss of appetite, and abdominal pain. Past medical history and family history are unremarkable. The patient is 1.8 m (5'11") tall and weighs 54 kg (120 lb). Results from laboratory studies 3 years ago were normal. At this visit, his glucose level is 550 mg/dL (reference range: 70-100 mg/dL), and urinalysis reveals ketone bodies (reference range: negative). The most likely underlying cause of this patient's condition is
- a. decreased insulin sensitivity
 b. increased leptin resistance
 c. loss of insulin promoter factor
 d. pancreatic islet cell destruction
 e. presence of an insulinoma

10. A 56-year-old multiparous woman presents to the office to discuss menopause management. It has been 18 months since her last menstrual cycle. She is especially concerned about her risk of bone fractures, as several of her older female relatives have had this issue. Past medical history is negative for hypertension and osteoporosis. She does not smoke cigarettes, and she drinks 1 or 2 alcoholic beverages per month. In addition to calcium and vitamin D, which of the following pharmacologic agents is most appropriate to reduce this patient's risk of bone fractures?

- a. alendronate
- b. estrogen
- c. magnesium sulfate
- d. progesterone
- e. teriparatide

Endocrine System and Metabolism Answer Key

| Question | Answer |
|----------|--------|
| 6. | e |
| 7. | d |
| 8. | d |
| 9. | d |
| 10. | a |

Nervous System and Mental Health

11. A 14-year-old girl is brought to the office with a 1-month history of nausea, vomiting, severe headaches, and lethargy that have been increasing in frequency and severity. She denies any head trauma or participation in contact sports. Physical examination reveals papilledema and a normal cup-to-disc ratio. A CT scan of the head reveals dilation of both lateral ventricles and the third ventricle. What is the most likely cause of this patient's presentation?
- obstruction of the arachnoid villi
 - obstruction of the cerebral aqueduct
 - obstruction of the lateral aperture of the fourth ventricle
 - occlusion of the interventricular foramen
 - overproduction of cerebrospinal fluid by the choroid plexus
12. A 78-year-old woman is brought to the emergency department with sudden-onset weakness of the right side of her face and right upper extremity. The patient is right-handed. Past medical history reveals atrial fibrillation. The patient's speech is labored and only contains short sentences and phrases. She understands questions but cannot repeat them. Physical examination reveals hemiplegia and sensory loss of the right side of the face and right upper extremity. A lesion in which of the following brain structures is most likely responsible for these findings?
- left arcuate fasciculus
 - left inferior frontal gyrus
 - left superior temporal gyrus
 - right arcuate fasciculus
 - right inferior frontal gyrus
 - right superior temporal gyrus
13. A 32-year-old woman presents to the office with a 2-week history of an inability to feel her right hand. Examination of the upper extremities reveals:
- Intact pinprick sensation bilaterally
 - Intact vibratory sensation on the left
 - Absent vibratory sensation at the right medial and lateral forearm and at the dorsum, palm, and digits of the right hand
 - +2/4 deep tendon reflexes at the biceps brachii, triceps brachii, and brachioradialis bilaterally
- Damage to which of the following structures is the most likely cause of this patient's presentation?
- anterolateral system on the left
 - cuneate fasciculus on the right
 - median nerve on the right
 - posterior root at C6-C8 on the right
 - posterior spinocerebellar tract on the right

14. A 20-year-old man is brought to the emergency department with a 48-hour history of nausea, vomiting, abdominal pain, dark stools, and blurred vision. Questioning reveals that he was at a party 2 days ago and drank homemade alcohol. The patient becomes comatose during the physical examination. Which of the following neuronal structures is most likely damaged in this patient?

- a. amygdala
- b. caudate nucleus
- c. putamen
- d. substantia nigra
- e. thalamus

15. A 62-year-old woman is evaluated in her extended care facility for a health maintenance examination. Past medical history reveals a stroke 2 years ago. Physical examination reveals:

- Babinski sign on the left
- Paresis of the left upper and lower extremities
- Laterally deviated right eye
- Dilated right pupil

Dilation of this patient's pupil is most likely caused by damage to which of the following structures?

- a. nucleus of the trochlear nerve
- b. postganglionic parasympathetic fibers
- c. postganglionic sympathetic fibers
- d. preganglionic parasympathetic fibers
- e. preganglionic sympathetic fibers

16. A 10-year-old girl is a participant in a research study about the ease of learning a second language at an early age. The study tests the hypothesis that the strengthening of neuronal synapses during learning is due to the retrograde function of which of the following messengers?

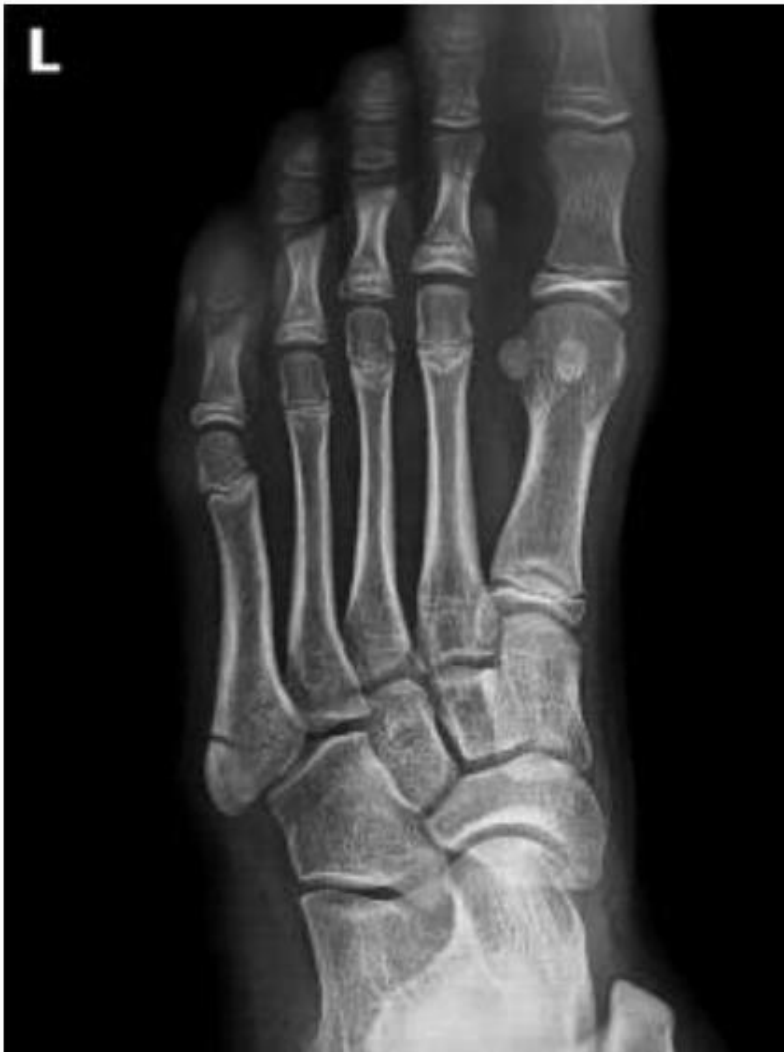- a. AMPA
- b. calcium
- c. cGMP
- d. nitric oxide
- e. NMDA

Nervous System and Mental Health Answer Key

| Question | Answer |
|-----------------|---------------|
| 11. | b |
| 12. | b |
| 13. | b |
| 14. | c |
| 15. | d |
| 16. | d |

Musculoskeletal System

17. A 22-year-old woman presents to the emergency department 1 hour after she injured her left foot while playing beach volleyball. She says that she jumped and landed with her left ankle turned inward. She has difficulty everting the foot. Examination reveals tenderness at the lateral aspect of the midfoot. A radiograph of the left foot reveals the findings shown in the exhibit.



Which of the following muscles is most likely damaged as a result of this patient's avulsion fracture?

- a. fibularis brevis
- b. fibularis longus
- c. flexor digiti minimi brevis
- d. flexor digitorum brevis
- e. tibialis anterior
- f. tibialis posterior

18. A 70-year-old woman presents to the office for a health maintenance examination. The patient is retired and lives independently, but she has not been able to take her usual walks lately due to extreme winter weather. Review of systems reveals vague gastrointestinal irritation for the past 2 months and no other complaints. Vital signs reveal:

| | |
|------------------|-----------------|
| Temperature | 37.0°C (98.6°F) |
| Blood pressure | 135/76 mmHg |
| Heart rate | 70/min |
| Respiratory rate | 19/min |

Complete blood count and peripheral blood smear results are normal. A DXA scan reveals a T-score of -2.6. Which of the following dietary supplements is most appropriate for this patient?

- a. folic acid
- b. glucosamine-chondroitin
- c. magnesium
- d. vitamin B12
- e. vitamin D

19. A 15-year-old girl is brought to the emergency department with a 2-hour history of pain, swelling, and bruising over the lateral aspect of her left ankle. She says that she landed awkwardly after she jumped during a basketball game. Examination reveals that the anterior, inferior aspect of the lateral malleolus is the point of maximum tenderness. An anterior drawer test at the ankle produces a positive result; an external rotation test result is negative. A radiograph of the ankle reveals no fracture. The excessive movement that caused this patient's injury most likely occurred at which of the following joints?

- a. calcaneocuboid
- b. cuneonavicular
- c. subtalar
- d. talocrural
- e. tibiotalar

20. A 52-year-old woman presents to the office with a 1-month history of bilateral diplopia and fatigue that worsen on exertion and improve with rest. Ophthalmic examination reveals bilateral ptosis. The physiologic mechanism of this patient's condition is due to autoantibodies against which of the following receptors?
- G protein-coupled
 - nicotinic
 - thyroid-stimulating hormone
 - toll-like
 - tyrosine kinase
21. A 5-year-old boy is brought to the office with a 4-day history of pain in his lower extremities that began after a soccer match. Vital signs are normal. Examination of the lower extremities reveals hypersensitivity to touch. Radiographs of the lower extremities reveal multiple hairline fractures. Genetic testing reveals an abnormality on one allele of a gene that encodes an extracellular matrix protein. Which of the following molecular events most likely underlies the cause of this patient's presentation?
- chromosomal duplication
 - chromosomal translocation
 - dominant negative mutation
 - missense mutation
 - splice-site mutation
22. A 75-year-old man is admitted to the hospice care center. He has terminal bone cancer and is in pain. A transdermal patch for pain relief is recommended. Which of the following drugs is most appropriate to give this patient by this route?
- fentanyl
 - hydrocodone
 - hydromorphone
 - methadone
 - morphine

Musculoskeletal System Answer Key

| Question | Answer |
|----------|--------|
| 17. | a |
| 18. | e |
| 19. | c |
| 20. | b |
| 21. | c |
| 22. | a |

Genitourinary/Renal System

23. A 39-year-old woman takes a flight to the Rocky Mountains. The next day, she begins a climb to a high mountain peak. As she rises to higher altitudes, she becomes increasingly hypoxic and anemic. Which hormone-producing cells are most strongly induced during the ascent to offset these symptoms?
- parathyroid chief cells
 - pituitary gonadotrophs
 - renal macula densa cells
 - renal peritubular cells
 - thyroid follicular cells
24. A 67-year-old woman presents to the office with a 2-day history of frequent burning on urination and suprapubic pain. Abdominal examination reveals tenderness in the lower quadrants. Urinalysis reveals turbid urine. Microscopy of the urine reveals a leukocyte count of 8/hpf (reference range: 0-5/hpf). A urine culture reveals fermenting growth on MacConkey agar. Results from urease and citrate utilization tests are positive. What is the most likely etiology?
- Escherichia coli*
 - Klebsiella pneumoniae*
 - Proteus mirabilis*
 - Staphylococcus saprophyticus*
 - Ureaplasma urealyticum*
25. A 28-year-old man is brought to the emergency department after he was found in the wilderness. The patient was lost for 2 days and was deprived of food and water. Physical examination reveals dry mucous membranes. Laboratory studies are most likely to reveal which of the following results?

| | Urine Volume | Urine Osmolality | Free Water Clearance | Antidiuretic Hormone |
|-----------|--------------|------------------|----------------------|----------------------|
| A. | decreased | increased | increased | increased |
| B. | decreased | increased | decreased | increased |
| C. | decreased | decreased | decreased | decreased |
| D. | increased | increased | increased | increased |
| E. | increased | decreased | decreased | decreased |

- A
- B
- C
- D
- E

26. A 37-year-old woman presents to the office with a 3-day history of pain and burning on urination. Past medical history is unremarkable. Laboratory studies reveal a creatinine level of 1.20 mg/dL (reference range: 0.45-0.75 mg/dL) and a blood urea nitrogen level of 29 mg/dL (reference range: 6-20 mg/dL). Urine dipstick test results are positive for leukocyte esterase (reference range: negative). Which of the following treatment agents is most likely to precipitate in the renal tubules?

- a. ampicillin
- b. cephalexin
- c. sulfamethoxazole
- d. tetracycline
- e. trimethoprim

27. A 50-year-old woman presents to the office for an annual health maintenance examination. The patient has no complaints. Review of records reveals that her blood pressure has steadily increased over the past decade. Vital signs reveal a blood pressure of 149/101 mmHg and a heart rate of 65/min. A loop diuretic is prescribed. The most likely adverse effect of this drug is determined by measuring plasma levels of which of the following substances?

- a. glucose
- b. potassium
- c. protein
- d. pyruvate
- e. sodium

28. A 60-year-old woman is brought to the emergency department by EMS after she was found convulsing behind an automobile repair shop. EMS report that there was an empty bottle of antifreeze next to her. Past medical history reveals alcohol use disorder. The patient is homeless. Initial laboratory studies reveal:

| Test | Patient's Value | Reference Range |
|--------------------|-----------------|-----------------|
| pH | 7.20 | 7.35-7.45 |
| Bicarbonate | 20 mEq/L | 22-29 mEq/L |
| Creatinine | 1.80 mg/dL | 0.62-1.10 mg/dL |

She is admitted to the hospital. Crystals are observed in the patient's urine 24 hours after admission. Which of the following toxic agents is most likely present in this patient's blood?

- a. acetaldehyde
- b. cystine
- c. formate
- d. methylmalonate
- e. oxalate

Genitourinary/Renal System Answer Key

| Question | Answer |
|-----------------|---------------|
| 23. | d |
| 24. | b |
| 25. | b |
| 26. | c |
| 27. | b |
| 28. | e |

Gastrointestinal (GI) System and Nutritional Health

29. A 3-year-old boy is brought to the office with a 3-day history of abdominal pain and a 5-day history of bloody stools. Physical examination findings are normal. An abdominal ultrasound reveals a 2-cm diverticulum that projects from the midgut. The diverticulum is surgically removed. Histologic examination of the diverticulum is most likely to reveal
- bone marrow
 - gastric mucosa
 - respiratory epithelium
 - submucosa of the ascending colon
 - transitional epithelium
30. A 4-week-old girl is admitted to the pediatric intensive care unit with a 4-day history of poor feeding, wheezing, and bulky, foul-smelling stools. She was recently diagnosed in the emergency department with right lobe pneumonia. Her mother says that the patient had an abnormal finding on the newborn screening blood test but that she did not follow up with the pediatrician. A sweat chloride test reveals 3 times the normal amount. This patient most likely has a defect in
- dibasic amino acid transporters
 - neutral amino acid transporters
 - pancreatic zymogen secretion
 - small intestinal peptidase secretion
 - stomach pepsin secretion
31. A 2-year-old girl is brought to the office by her father with a 2-day history of abdominal pain, vomiting, and diarrhea. The father reports that the patient had a fever with temperatures up to 39.2°C (102.6°F) 4 days ago; at that time, he administered an over-the-counter antipyretic analgesic. Questioning reveals that the patient kept taking the treatment after her fever subsided in order to alleviate her abdominal pain, which has become more severe. Physical examination reveals right-sided subcostal pain and tender hepatomegaly. Laboratory studies reveal an alanine aminotransferase level of 40 U/L (reference range: 7-35 U/L) and an aspartate aminotransferase level of 65 U/L (reference range: 20-60 U/L). Which of the following mechanisms is the most likely cause of this patient's symptoms?
- depletion of glutathione
 - high glucuronidation
 - high sulfation
 - selective COX-1 inhibition
 - selective COX-2 inhibition

32. A 63-year-old man is brought to the office by his spouse with a 2-week history of irritability, difficulty balancing, and tingling in his feet. His spouse says that he has become very forgetful, often seems confused, and explains his surroundings by making up stories. Past medical history reveals severe alcohol use disorder. Vital signs reveal:

| | |
|----------------|-----------------|
| Temperature | 37.0°C (98.6°F) |
| Blood pressure | 125/75 mmHg |
| Heart rate | 68/min |
| Respiratory | 16/min |

Neurologic examination reveals an ataxic gait, slow pupillary light reflex, and recent event recall deficits. A deficiency in which of the following substances is most likely responsible for this patient's presentation?

- a. pantothenic acid
- b. thiamine
- c. vitamin B₆
- d. vitamin B₁₂
- e. vitamin C

33. A 4-year-old boy is brought to the office by his guardian with a 1-month history of irritability and swelling of the ankles and abdomen. His guardian is also concerned about his slow growth rate. Questioning reveals that the patient has a poor appetite and mainly eats rice, bread with butter, and juice. His weight is at the 10th percentile, and his subcutaneous fat is normal. Physical examination reveals:

- Dry, flaky skin
- Reddish hair
- Pitting edema and skin lesions of the legs and feet
- Hepatomegaly
- Ascites
- Hypotonia in all extremities

What is the most likely underlying cause of this patient's presentation?

- a. adequate calories, insufficient carbohydrate intake
- b. adequate calories, insufficient lipid intake
- c. adequate calories, insufficient protein intake
- d. inadequate calories, sufficient carbohydrate intake
- e. inadequate calories, sufficient lipid intake
- f. inadequate calories, sufficient protein intake

34. A 42-year-old woman presents to the office with a 2-month history of diarrhea that occurs every 3 or 4 days and is frequently accompanied by cramping and bloating. The most appropriate treatment for this patient works by which of the following mechanisms of action?
- a. antagonism of β_2 -adrenergic receptors
 - b. antagonism of 5-HT₃ receptors
 - c. inhibition of dopamine D₂ receptors
 - d. stimulation of α_2 -adrenergic receptors
 - e. stimulation of muscarinic M₂ receptors

Gastrointestinal (GI) System and Nutritional Health Answer Key

| Question | Answer |
|----------|--------|
| 29. | b |
| 30. | c |
| 31. | a |
| 32. | b |
| 33. | c |
| 34. | b |

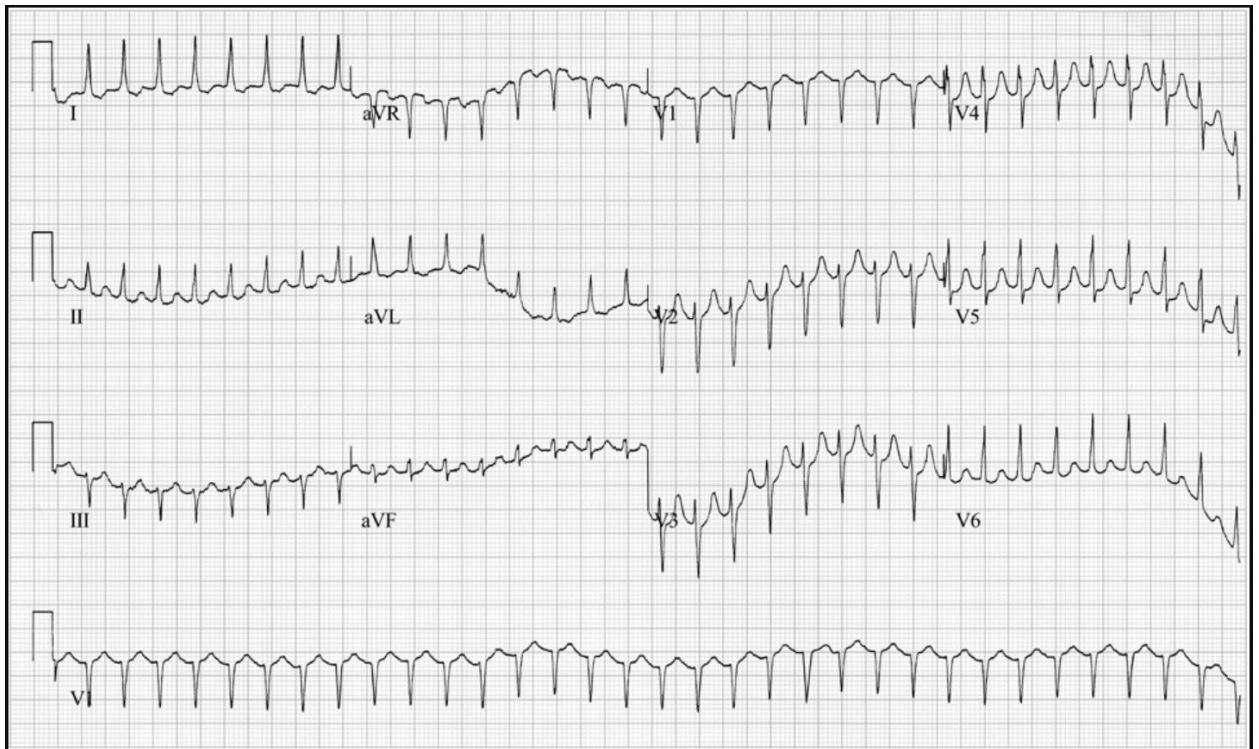
Cardiovascular and Hematologic Systems

35. A 22-month-old girl is brought to the office with a 3-week history of easy fatigability. Review of records reveals normal vital signs at her 18-month visit, however cyanosis of the lips was noted at that time. An echocardiogram reveals a 1.0×1.5 -cm defect in the inferior portion of the atrial septum, immediately superior to the atrioventricular valves. What is the most likely diagnosis?
- patent foramen ovale
 - patent ostium primum
 - patent ostium secundum
 - sinus venosus defect
 - ventricular septal defect
36. A 25-year-old woman presents to the office with a 2-day history of severe abdominal and pelvic pain. Past medical history reveals sickle cell disease. Abdominal examination reveals:
- Normoactive bowel sounds
 - Diffuse tenderness
 - No distention
 - No guarding
 - No rebound
 - No organomegaly
- What is the most likely cause of this patient's abdominal pain?
- acute pancreatitis
 - disseminated intravascular coagulation
 - hemolytic episodes
 - peritonitis
 - vasoocclusive hypoxic injury
37. An enlarged heart is noted during the autopsy of an 82-year-old man. Light microscopy of a tissue sample reveals myocytes with step-like disks. The transverse portion of these disks is primarily composed of which of the following structural components?
- claudins
 - connexins
 - desmosomes
 - gap junctions
 - occludins

38. A 32-year-old woman presents to the emergency department with a 6-month history of typically infrequent palpitations and dizziness when she stands. Questioning reveals that she has experienced 4 episodes in the past week. Seated vital signs reveal:

| | |
|------------------|------------|
| Blood pressure | 88/72 mmHg |
| Heart rate | 200/min |
| Respiratory rate | 20/min |

An electrocardiogram is obtained, as shown in the exhibit.



Which of the following factors most likely contributes to this patient's dizziness?

- a. decreased systemic vascular resistance
- b. decreased ventricular ejection fraction
- c. decreased ventricular stroke volume
- d. increased ventricular afterload
- e. increased ventricular contractility

39. A 7-year-old boy is brought to the office by his parents for an annual health maintenance examination. Past medical history reveals megaloblastic anemia. He has been treated with vitamin B₆ and vitamin B₁₂ for the past 2 years, but the anemia has not improved. Review of records reveals delayed growth and development since the age of 4. He is 1.2 m (3'9") tall and weighs 21 kg (46 lb). On examination, the patient appears pale, weak, and lethargic. He has an elevated urine orotic acid level. What is the most appropriate treatment for this patient?
- a. adenine
 - b. folic acid
 - c. S-adenosylmethionine
 - d. thiamine
 - e. uridine

Cardiovascular and Hematologic Systems Answer Key

| Question | Answer |
|----------|--------|
| 35. | b |
| 36. | e |
| 37. | c |
| 38. | c |
| 39. | e |

Respiratory System

40. A 14-year-old girl is brought to the emergency department with a 1-week history of cough, dyspnea, and fever with temperatures up to 39.4°C (103.0°F). Past medical history reveals cystic fibrosis. Review of records reveals recurrent hospitalizations. Her respiratory rate is 24/min. Lung auscultation reveals bilateral wheezes. A sputum culture reveals *Pseudomonas aeruginosa*. Which of the following pathophysiologic changes is most likely responsible for increased lung colonization in this patient?
- altered mucociliary clearance
 - chronic hypoxemia
 - increased pulmonary chloride ion concentration
 - pulmonary necrosis
 - worsening bronchospasms
41. A 4-year-old girl is brought to the emergency department by her parent with a 4-day history of a sore throat and a 1-hour history of respiratory distress. Questioning of the parent reveals that they immigrated to the United States 3 months ago. The patient has not received any immunizations. Physical examination reveals cervical lymphadenopathy. The soft palate is covered by a friable, grayish-white membrane. Cervical lymphadenopathy is also noted. What is the most likely etiology?
- Bordetella pertussis*
 - Clostridium tetani*
 - Corynebacterium diphtheriae*
 - Haemophilus influenzae*
 - Streptococcus pneumoniae*

42. A 10-year-old boy is brought to the office with a 2-day history of fever, muscle aches, sore throat, and cough. Vital signs reveal:

| | |
|------------------|------------------|
| Temperature | 39.2°C (102.5°F) |
| Blood pressure | 100/70 mmHg |
| Heart rate | 120/min |
| Respiratory rate | 28/min |

Physical examination reveals:

- Clear lung sounds
- Erythematous, edematous nasal turbinates with clear discharge
- Erythematous oropharynx without exudate

A rapid diagnostic immunoassay of nasal secretions reveals antigens from a segmented RNA virus. What is the most likely etiology?

- a. coronavirus
- b. influenza virus
- c. parainfluenza virus
- d. respiratory syncytial virus
- e. rhinovirus

43. A 32-year-old woman is brought to the emergency department by EMS, who found her in an unconscious state of unknown duration. A needle and syringe were found next to the patient. Vital signs reveal:

| | |
|------------------|------------|
| Blood pressure | 80/40 mmHg |
| Heart rate | 56/min |
| Respiratory rate | 4/min |

Physical examination reveals perioral cyanosis. The lungs are clear to auscultation. Initiation of oxygen therapy is most likely to cause which of the following changes in this patient's blood oxygen levels?

| | Arterial PO ₂ | Arterial Hemoglobin Saturation | Dissolved Oxygen Content |
|-----------|--------------------------|--------------------------------|--------------------------|
| A. | increased | increased | increased |
| B. | increased | no change | no change |
| C. | increased | no change | increased |
| D. | no change | no change | increased |
| E. | no change | increased | no change |
| F. | no change | increased | increased |

- a. A
- b. B
- c. C
- d. D
- e. E
- f. F

44. A 34-year-old woman presents to the office with a 36-hour history of nasal congestion, sore throat, and fatigue. Vital signs reveal:

| | |
|------------------|-----------------|
| Temperature | 37.7°C (99.9°F) |
| Blood pressure | 115/75 mmHg |
| Heart rate | 70/min |
| Respiratory rate | 16/min |

The most appropriate medication for this patient's nasal symptoms works by which of the following mechanisms?

- a. α_1 -adrenergic receptor agonist
- b. α_2 -adrenergic receptor antagonist
- c. β_1 -adrenergic receptor antagonist
- d. β_2 -adrenergic receptor agonist
- e. muscarinic M₂ receptor agonist

45. An 82-year-old woman presents to the office with a 1-year history of worsening cough and shortness of breath. She has a 45 pack-year history of cigarette smoking and quit smoking 15 years ago. Vital signs reveal:

| | |
|-----------------------------|-----------------|
| Temperature | 36.8°C (98.2°F) |
| Blood pressure | 140/90 mmHg |
| Heart rate | 105/min |
| Oxygen saturation (at rest) | 92% on room air |
| Oxygen saturation (walking) | 84% on room air |

ECG findings are normal. Her FEV₁/FVC ratio is 65% of predicted. The most appropriate inhaled medication for this patient works by blocking which of the following receptors?

- a. β_1 -adrenergic receptors
- b. glucocorticoid receptors
- c. histamine H₁ receptors
- d. leukotriene receptors
- e. muscarinic receptors

Respiratory System Answer Key

| Question | Answer |
|----------|--------|
| 40. | a |
| 41. | c |
| 42. | b |
| 43. | a |
| 44. | a |
| 45. | e |

Integumentary System

46. A 24-year-old man presents to the office with a 2-week history of a rash on his scalp and knees. An over-the-counter steroid cream has provided minimal improvement. Past medical history is unremarkable except for streptococcal pharyngitis treated with antibiotics 1 month ago. Family history reveals that his mother has had similar rashes. Examination of the scalp and knees reveals erythematous patches of skin covered with thick, silvery scales. This patient's condition is most likely due to which of the following underlying mechanisms?
- a. decreased apoptosis in the stratum spinosum
 - b. increased mitosis in the stratum basale
 - c. longer cell cycles in the stratum lucidum
 - d. loss of tight junctions in the stratum corneum
 - e. reduced keratin synthesis in the stratum granulosum
47. A 42-year-old woman presents to the office with a 3-day history of a painful rash on her right thumb and lateral forearm. She reports pain and tingling in this area for 12 hours prior to the development of the rash. A virus has most likely been reactivated in the ganglion at which of the following spinal levels?
- a. C4
 - b. C5
 - c. C6
 - d. C7
 - e. C8
48. A 37-year-old man presents to the office for evaluation of a mole that appeared 2 months ago on the left breast. He says that he noticed blood on the mole 2 weeks ago. Vital signs are normal. Examination reveals an elevated, 9-mm, brown lesion with variegate pigmentation. The lesion has irregular, asymmetrical borders. Which of the following oncogenes is most likely responsible for the growth of this patient's mole?
- a. APC
 - b. BRAF
 - c. BRCA1
 - d. RB1
 - e. SMAD4

49. A 35-year-old man presents to the office with a 2-day history of open sores on both hands. The patient says that he noticed a hard, painless bump under the skin on his hand 2 weeks ago but did not seek medical treatment. Social history reveals that he works as a landscaper. Examination of the hands reveals several ulcerating lesions with odorless, purulent discharge along the draining lymphatic vessels. Culture of a tissue sample on Sabouraud dextrose agar is positive for growth with distinct morphology at room temperature versus 37.0°C (98.6°F). What is the most likely diagnosis?

- a. candidiasis
- b. cutaneous leishmaniasis
- c. nocardiosis
- d. nontuberculous mycobacterial infection
- e. sporotrichosis

50. A 15-year-old boy is brought to the office with a 1-month history of mild, noninflammatory acne. Examination reveals scattered pustules on the scalp and face. Topical retinoic acid is prescribed. It is most appropriate to counsel this patient on which of the following adverse effects?

- a. easy bruising
- b. epidermal thinning
- c. erythema
- d. freckling
- e. hair loss

Integumentary System Answer Key

| Question | Answer |
|----------|--------|
| 46. | b |
| 47. | c |
| 48. | b |
| 49. | e |
| 50. | c |